

ETD Archive

---

2019

## Voice Disorders Secondary to Thyroidectomy: A Case Study

Samantha D'agostino  
*Cleveland State University*

Follow this and additional works at: <https://engagedscholarship.csuohio.edu/etdarchive>



Part of the [Speech and Hearing Science Commons](#), and the [Speech Pathology and Audiology Commons](#)

**How does access to this work benefit you? Let us know!**

---

### Recommended Citation

D'agostino, Samantha, "Voice Disorders Secondary to Thyroidectomy: A Case Study" (2019). *ETD Archive*. 1160.

<https://engagedscholarship.csuohio.edu/etdarchive/1160>

This Thesis is brought to you for free and open access by EngagedScholarship@CSU. It has been accepted for inclusion in ETD Archive by an authorized administrator of EngagedScholarship@CSU. For more information, please contact [library.es@csuohio.edu](mailto:library.es@csuohio.edu).

VOICE DISORDERS SECONDARY TO THYROIDECTOMY: A CASE STUDY

SAMANTHA D'AGOSTINO

Bachelor of Arts in Speech and Hearing Science

The Ohio State University

May 2017

Submitted in partial fulfillment of requirements for the degree of

MASTER OF ARTS IN SPEECH-LANGUAGE PATHOLOGY AND AUDIOLOGY

at

CLEVELAND STATE UNIVERSITY

May 2019

We hereby approve this thesis for

SAMANTHA LYNN D'AGOSTINO

Candidate for the Master of Arts in Speech-Language Pathology and Audiology degree

for the Department of Speech and Hearing

and CLEVELAND STATE UNIVERSITY'S

College of Graduate Studies by

---

Thesis Chairperson, Violet O. Cox, Ph.D., CCC-SLP

---

Department & Date

---

Thesis Committee Member, Andrew Lammers., Ph.D.

---

Department & Date

---

Thesis Committee Member, Brigette Wilson, CCC-SLP

---

Department & Date

Student's Date of Defense: May 8th, 2019

# VOICE DISORDERS SECONDARY TO THYROIDECTOMY: A CASE STUDY

SAMANTHA D'AGOSTINO

## ABSTRACT

The thyroid is an important gland that aids in development. Located anteriorly at the base of the neck, the thyroid produces hormones that regulate metabolism. Thyroid dysfunction can lead to excess or reduced production of hormones known as hyper and hypothyroidism. Usually affecting women, hyper and hypothyroidism can be life-threatening. A well-known treatment is a thyroidectomy, or removal of the thyroid gland. Many people report vocal change secondary to thyroidectomy. Dysfunction can result from intubation during surgery or damage to laryngeal nerves and/or muscles. A participant's low intensity and difficulty with projection prompted a case-study to examine the laryngeal area for differences. *KayPENTAX Visi-Pitch* and *Videostrobe* instrumentation were utilized to provide instant video feedback and acoustic parameters that were compared to typical parameters/structures. Using videostroboscopy, a rigid scope was placed over the base of the tongue containing a miniature camera. The participant phonated syllables such as "ee" and "ah" from low to high pitch ranges at Cleveland State University (CSU). A voice sample was also analyzed through *Visi-Pitch* instrumentation to assess parameters including jitter, shimmer, and fundamental frequency among others. Structural and acoustic parameters from Cleveland State were compared to results from an Ear, Nose, and Throat (ENT) doctor also utilizing videostroboscopy. Both CSU and ENT results note structural and acoustic differences despite no reported laryngeal nerve damage post-thyroidectomy.

## TABLE OF CONTENTS

	Page
ABSTRACT.....	iv
LIST OF TABLES .....	vi
LIST OF FIGURES .....	vii
CHAPTER	
I.    Introduction .....	1
II.   Methods.....	12
III.  Results.....	17
IV.  Discussion.....	26
V.   Conclusion.....	28
REFERENCES.....	30

LIST OF TABLES

Table	Page
I. Cleveland State University (CSU) via Rigid Scope Videostroboscopy.....	19
II. ENT vs CSU Results of Videostroboscopy.....	22
III. Visi-Pitch Measures.....	24
IV. IV. Parameters vs Typical Range.....	27

## LIST OF FIGURES

Figure	Page
1. Voice Handicap Index.....	16
2. Voice-Vibratory Assessment with Laryngeal Imaging (VALI)-Stroboscopy.....	23
3. Multi-Dimensional Voice Diagram.....	25

## CHAPTER I

### INTRODUCTION

The thyroid gland plays an essential role in metabolism, growth, and development of the body. The thyroid gland is located at the base of the neck, below the larynx. Dysfunction of this gland can result in goiters and effects can be challenging to manage. As a result of dysfunction, hyperthyroidism or hypothyroidism may occur. Hypothyroidism is the most common thyroid problem where antibodies attack and damage thyroid cells. Production of thyroid hormone output is therefore reduced as a result of such attack. Hyperthyroidism, conversely, produces excess hormone output which can produce symptoms including weight loss, fatigue, nervousness, irritability, insomnia, tremors, and rapid heart pounding. Antibodies attack thyroid cells and stimulate production of excess hormones. Eye problems can co-occur with thyroid dysfunction as antibodies attack other muscles such as eye tissue. Eye tissue is inflamed and causes an increase in pressure, resulting in protruding eyes. Graves' disease or Thyroid Eye Disease (TED) is an autoimmune disease that mainly affects women. TED can cause pain, proptosis, eyelid swelling, non-real exposure, and optic difficulties (Kashkouli et al., 2011). Vital et al., view hyperthyroidism as a life-threatening condition mostly caused by Graves' disease (2017).



Management of patients with both hyperthyroidism and Graves' can be difficult as "ideal" treatment without complications does not currently exist (Vital et al., 2017). According to Padur et al., a total thyroidectomy is the preferred treatment for various thyroid diseases (2016). Chun et al., concur that thyroidectomy is an effective procedure currently used to manage thyroid disease (2012). Treatment via total thyroidectomy provides the advantage of eliminating the risk of thyroid problem recurrence. According to Padur et al., (2016), an increasing number of total thyroidectomies are performed for benign cases. The safety of total thyroidectomy is controversial among surgeons as there is risk associated postoperatively with damage to various structures (Padur et al., 2016). Still, it is well known that success rates are highest when patients are treated with removal of the gland. Patients do not experience recurrence of hypo/hyperthyroidism symptoms if a complete total thyroidectomy is performed. Even though thyroidectomy has associated risk, recurrence is eliminated if the gland is removed.

There are risks associated with removal of the thyroid gland. Persistent voice problems post-thyroidectomy are commonly reported by patients. Vocal dysfunction is one of the main complaints following thyroidectomies (Soylu, Ozbas, Uslu, & Kocak, 2007; Stojadinovic et al., 2008; Holler & Anderson, 2014; Henry et al., 2010; Kim et al., 2012a; Park, Baek, & Jung, 2018; Awan, Helou, Stojadinovic, & Solomon 2011; Chun et al., 2012a). Vocal dysfunction can significantly impact the quality of life for persons experiencing dysphonia (Stojadinovic et al., 2008). Pitch, loudness, and vocal quality are considered important perceptual characteristics of the voice according to Roseberry-McKibbin, Hege, and Tellis (2019). Work by Roseberry-McKibbin et al., report that personality, intelligibility, and competence are often judged by such vocal parameters

(2019). Negative connotation is associated with dysphonia as voice disorders tend to affect vocal pitch, loudness, and quality. Following surgery, patients may report discomfort or difficulty with swallowing and/or vocal changes. These difficulties can be managed, but do not occur for all individuals who undergo thyroid removal.

Branches of cranial nerve X or the vagus nerve are commonly referenced for such difficulties. The vagus nerve contains motor, sensory, and mixed fibers. Motor fibers from CN X supply the digestive system, heart, lungs, pharynx, and larynx. The sensory fibers convey information from the digestive system, heart, trachea, bronchi, lower pharynx, larynx, and epiglottis (Roseberry-McKibbin et al., 2019). The Recurrent Laryngeal Nerve (RLN) is a branch of the vagus nerve that regulates the muscles of the larynx. Damage to the RLN during surgery can result in total or partial paralysis of the vocal folds (Roseberry-McKibbin et al., 2019). The Superior Laryngeal Nerve (SLN) is another branch of the vagus nerve, further branching out to the External Branch of the Superior Laryngeal Nerve (EBSLN). It is divided into internal/sensory, and external/motor components. The internal branch receives sensory information from the larynx above the vocal folds. The external branch innervates the cricothyroid muscle. Damage results in inability to change pitch. Vagus nerve damage can result in difficulty swallowing, paralysis of the velum, and/or voice problems. Voice problems could include aphonia, breathiness, roughness, and hoarseness among other voice disorders (Roseberry-McKibbin et al., 2019). Removal of the thyroid gland can cause damage to the vagus nerve and result in various swallowing, voice, and structural abnormalities or difficulties.

Described as a “more complex entity”, vocal changes were closely examined post-thyroidectomy by Soylu et al., (2007). Voice problems are commonly attributed to surgical trauma, laryngotracheal fixation of the strap muscles, endotracheal intubation, or trauma to the arytenoids during intubation (Stojadinovic et al., 2008a; Soylu et al., 2007; Henry et al., 2010). Similarly, possible causes of voice impairment after thyroidectomy without RLN damage include injury to the EBSLN, cricothyroid muscle, laryngotracheal fixation, endotracheal intubation, vocal cord edema or altered vascular supply, laryngoesophageal reflux, and/or cervical scar, local neck pain, and psychotic reaction to stress (Sung et al., 2018). Laryngoesophageal reflux occurs with dysfunction of the esophagus. Stomach contents backflow into the laryngeal vestibule, resulting in “reflux”. Symptoms of laryngoesophageal reflux include sore throat, difficulty swallowing, frequent throat clearing, irritation of the laryngeal area, and/or hoarseness. Patients are made aware of risks associated with removal of the thyroid; however, the goal of thyroidectomy is to manage thyroid/hormone function. Vocal change is an associated risk, however, not often the main concern with thyroid removal.

Damage to EBSLN can cause fatigue, hoarseness, breathy voice, and/or nodules (Kim et al., 2012). The removal of the thyroid gland together with intubation is said to modify the vascular supply and venous drainage of the larynx—resulting in decreased pitch postoperatively (Chun et al., 2012a; Soylu et al., 2007). Identification of RLN injury and EBSLN injury is said to be more complicated to identify (Kim et al., 2012). It has been reported that thyroidectomy is the most common cause of EBSLN injury, however diagnosis of EBSLN injury is difficult to diagnose as the symptoms are nonspecific according to Kim et al., (2012). The use of Laryngeal Electromyography

(EMG) has been accepted as an acceptable method to identify this type of nerve injury, however, it is an invasive and difficult procedure (Kim et al., 2012). Bowing, or atrophy of the vocal folds can result during high pitch phonation and lead to incomplete glottic closure (Kim et al., 2012). A voice analysis following surgery is simple and non-invasive. It provides objective data that can be translated into a visual graphic regarding changes in voice quality and/or frequency change (Kim et al., 2012).

Additionally, damage to various laryngeal muscles can contribute to voice dysfunction. Pitch change involves when the cricothyroid muscle lengthens and tightens during phonation to increase vocal fold tension. (Roseberry-McKibbin et al., 2019). Loss of cricothyroid muscle function could result in fatigue during phonation, hoarseness, and a loss of projection (Sinagra et al., 2004). Fatigue during phonation may be caused by additional effort needed to increase voice pitch as a compensatory maneuver. Slight anatomic changes are usually unnoticed during the operation but can produce phonatory changes perceived by the patients postoperatively (Sinagra et al., 2004). From this, Sinagra et al., concluded that despite nerve damage, objective characteristics in patients with a total thyroidectomy *are* present (2004). There may not be overt damage to the nerves, however, vocal differences are still present for some.

Unilateral Vocal Fold Paralysis (UVFP) is typically caused by damage of the RLN. Voice changes include hoarseness, low intensity, breathiness, and diplophonia (Lombard & Steinhauer, 2007). There is a technique utilized when RLN and/or UVFP is present. A study conducted by Lombard & Steinhauer, did not examine effects post-thyroidectomy, but the effect of twang production on physiologic, acoustic, and perceived voice handicap measures in speakers with hypophonia (2007). Lombard & Steinhauer

describe twang as the “bright, brassy, ringing voice quality commonly heard in country-western singing, witch cackling, and a child’s nya, nya taunt” (2007). It is also often equated with duck quacking. Physiologically, twang is produced by narrowing the epilarynx via constriction of the aryepiglottic sphincter. The acoustic outcome of narrowing this laryngeal vestibule is a clustering of the third, fourth, and fifth formants resulting in a higher amplitude of all vowel spectra (Lombard & Steinhauer, 2007). This narrowing contributes to a “boost” in the voice, resulting in greater intensity. This study examined maximum phonation time (MPT), sound pressure level (SPL), and the voice handicap index (VHI). According to this theory, the vocal tract enhances vocal fold vibration because the supraglottal pressure driving the airflow is “synchronous” with the velocity of the vocal folds (Lombard & Steinhauer, 2007). Constricting the aryepiglottic sphincter and forms an inertive vocal tract, the speaker can improve vocal fold oscillation, increase amplitude of the speaker’s/singer’s formant, and capitalize on the vocal ring necessary for resonant voice projection (Lombard & Steinhauer, 2007). The small glottis paired with the small epilarynx indicate twang should be an acoustically powerful voice quality (Lombard & Steinhauer, 2007). Contrary to breath support techniques for improvement with intensity, results from this study revealed that the use of twang quality as an intervention for hypophonia was a successful alternative for treatment/rehabilitation of a weak voice (Lombard & Steinhauer, 2007). If twang voice is utilized appropriately, this technique can be used as a compensatory strategy for weak vocal quality. Rather than using breathing techniques to achieve loudness, twang vocal quality can be used as a way to project without strain. This technique would be beneficial

for those who have difficulty achieving loudness, such as participants who have perceptual and structural differences post-operatively.

The Myoelastic-Aerodynamic Theory of Phonation states that the vocal folds vibrate due to the pressure of the air and elasticity of the vocal folds (Roseberry-McKibbin et al., 2019). Air flow out of the lungs is temporarily stopped, known as subglottic pressure. Buildup of subglottic pressure eventually blows the vocal folds apart and sets them into vibration. The air moves through the open but constricted vocal folds, the pressure between the two folds decreases, and the folds are sucked back together. The Bernoulli effect is caused by an increase speed of air passing through the vocal folds, with a decrease in pressure between the vocal folds causing the “sucking” motion of the vocal folds toward one another (Roseberry-McKibbin et al., 2019). A buildup of subglottic pressure aids in phonation and therefore a lack of glottic closure and subglottic pressure can result in reduced loudness. Gaps between the folds are present, and the glottis is not fully adducted. Air escapes and a breathy/weak voice could result. If there is damage to the vocal folds and/or vagus nerve during thyroidectomy, damage or dysfunction can occur. For example, if musculature contributing to movement/function of the true vocal folds is damaged during surgery, incomplete closure can result. Incomplete closure can lead to a decrease in subglottic pressure, resulting in the escape of air before an adequate amount is built up to produce a strong/loud vocal quality.

To observe if structures are functional or if abnormalities are present, specialized instruments provide visualization of laryngeal structures. Videolaryngostroboscopic (VLS) evaluation of the larynx provides visualization of vocal fold vibrations. It provides qualitative and quantitative data about vocal function and dysfunction or abnormalities

(Koçak, Semih Aydint, 1999, Soylu et al., 2007,). Various studies note decreased pitch post-thyroidectomy due to injury to the EBSLN (Kim et al., 2012a, Sung et al., 2018). Paralysis of the EBSLN causes difficulty with high pitch phonation, decreased pitch range including difficulties with singing and high ranges, volume reduction and voice fatigue (Sung et al., 2018). Even if one is not a singer, voice problems can affect a person's life and perception of oneself.

Videolaryngostroboscopy is often used to assess vocal fold motion impairment, bowing, inferior displacement of vocal fold, regularity and symmetry of the mucosal wave, and degree of glottic closure (Park et al., 2018). Following thyroidectomy, hypomobility and glottal insufficiency from vocal fold paralysis is often straightforward to diagnose via videostroboscopy. Mucosal wave, however, can be more difficult to diagnose. Results of a study examining function post-thyroidectomy reveal glottal insufficiency and increased amplitude and/or mucosal wave (Simpson, May, Green, Eller, & Jackson, 2011). Also called a "chasing wave", asymmetry of vibration is present. The recorded image is recommended to be played in slow motion to aid in detection of asymmetrical vibration (Simpson et al., 2011). Specialized instrumentation such as the videostrobe is often utilized to achieve this "slow motion" effect for analysis of the laryngeal area.

What are outcomes following thyroidectomy and intubation? What are the effects of endotracheal intubation on voice? There are significant changes of jitter and shimmer values following endotracheal intubation due to vocal cord edema (Sung et al., 2018). Sung et al., examined long-term subjective and objective voice outcomes following thyroidectomy without RLN palsy and also evaluated the effects of endotracheal

intubation on post-thyroidectomy voice impairment (2018). Significant changes of jitter and shimmer values after endotracheal intubation due to vocal fold edema were reported by Sung et al., (2018). Fundamental frequency, jitter, and shimmer did not change significantly after surgery in the control or case group. Shimmer was significantly worse for 12 months following thyroidectomy, except in the 1st week significantly between case and control groups. Highest fundamental frequency decreased significantly in the thyroidectomy group and returned to post-operative level by 12 months after surgery (Sung et al., 2018). Additionally, frequency range decreased significantly following thyroidectomy for a month and for 3 days for the control group. The most commonly affected acoustic parameter affected from this study was highest frequency and frequency range. This study examined parameters that contribute to perceptual voice changes.

A study by Holler & Anderson (2014) examined the overall prevalence and severity of voice and swallowing complaints among preoperative thyroidectomy patients using both subjective and objective measures. Compressive symptoms such as voice, swallowing, and airway complaints are thought to be secondary to thyroid pathologies and are accepted indications for a thyroidectomy (Holler & Anderson, 2014). Similarly, a study conducted by Sinagra et al., 2004 notes vocal fatigue during phonation as the most common symptom after thyroidectomy. 87% (or 40 patients) indicated voice changes pre vs post-surgery (Sinagra et al., 2004). Many studies report improvement or resolution of compressive symptoms following thyroidectomy; however, some patients continue to experience voice and swallowing complaints postoperatively (Holler & Anderson, 2014).



Some patients report vocal change and swallowing difficulties despite preservation of laryngeal nerves (Park et al., 2018). Stojadinovic et al., conducted a study that evaluated patient-reported and clinician-determined voice assessments in identifying post-thyroidectomy dysphonia (2008). Results revealed voice alterations are common after operation, despite preservation of laryngeal nerves. In such study, 30% of patients suffered early and 14% suffered lasting functional voice changes after thyroid resection in absence of major laryngeal nerve injury (Stojadinovic et al., 2008a). Henry et al., reiterates that while laryngeal nerve injuries account for a large portion of voice problems and are well-established, there are patients who have long-term negative voice outcomes without evidence of injury (2010).

Non-neurological causes of impaired voice after thyroid surgery are often unrecognized as voice issues are often relied via patient report. A commonly used tool regarding personal perception of voice is the Voice Handicap Index (VHI). The Voice Handicap Index is commonly used to rate the influence of voice on a person's life. Change of symptoms, a surgeon's awareness, familiarity of dysphonia, and interpretation of laryngoscopic findings are important as knowledge of these subjects can be limited (Henry et al., 2010). Due to these limitations, dysphonia or changes in voice are difficult to recognize if surgery reports no damage. Identification and early referral for a comprehensive voice exam could lead to an overall improved quality of life, prevent secondary injuries, and identify patients who may benefit from voice therapy (Henry et al., 2010).

The present study aims to extend the findings of vocal change post-thyroidectomy despite preservation of the laryngeal nerve as a case study. This study will investigate the

vocal characteristic as measured by Visi-Pitch instrumentation and provide visualization of the larynx via rigid scope videostroboscopy.

## CHAPTER II

### METHODS

The investigation, materials, and procedures for this study were approved by the Institutional Review board (IRB) of Cleveland State University. There was not a financial incentive for participation.

#### **Participant**

This is a self-study. The participant in the current study was premature (born at 24 weeks) and was intubated for 42 days after birth. The participant was diagnosed with Graves' Disease at age 15. Subsequently, total thyroidectomy was performed to manage symptoms of Graves/hyperthyroidism on December 18, 2009. Perceptual vocal changes were observed by the participant and by others. Participant experienced vocal fatigue at end of the day and vocal tension at baseline following thyroid removal. Participant also reported noticeable difficulty with projection. Participant is a Caucasian female, height is 4'11" and weight is 100 lbs.

#### **Instrumentation**

The *KayPentax Visi-Pitch IV* is a computerized recorder that captures the acoustic signal and analyzes it in real-time. It measures and stores vocal information such as fundamental frequency, amplitude, and perturbation measures of jitter and shimmer

(measured in decibels (dB) and percentages). The *Visi-Pitch* measures dynamic range, intensity, frequency variability, pitch, and loudness. This tool is non-invasive and provides instant visual feedback (Roseberry-McKibbin et al., 2019). With the Visi-Pitch, the patient speaks into a microphone and frequencies are displayed on a monitor. Fundamental frequency, Maximum Phonation Time, jitter, shimmer and other acoustic measures will be obtained using Visi-Pitch instrumentation.

The *KayPentax Rhino-Laryngeal Stroboscope* is a device used to complete a visual examination of the laryngeal area, in particular the vocal folds. Videostroboscopy is often used to assess vocal folds for damage or dysfunction. Overall vocal quality is subjective and based on degrees of clarity, breathiness, strain, loudness, pitch and regularity of vibration. A rigid scope is inserted over the base of the tongue containing a miniature camera and observes the oral cavity during phonation. Real-time movement of the vocal folds is captured on a computer screen for visualization.

### **Pitch (Frequency)**

Frequency is the number of cycles per second and is the rate at which the vocal folds vibrate. Higher frequencies have more cycles per second and lower frequencies have less cycles per second. Pitch is the perceptual correlate to frequency and is typically described as “high” or “low” in terms of voice. Pitch is based on the frequency of vibrations, known as fundamental frequency. Speaking Fundamental Frequency (SFF) is considered the participant’s habitual pitch or “typical/natural” pitch. Pitch is determined by mass, tension, and elasticity of the vocal folds. Higher pitch results when the vocal folds are thinner and/or more tense, while lower pitch results with thicker and/or more lax vocal folds (Roseberry-McKibbin et al., 2019). Frequency can stay constant with

changing pitch as a result of the vocal tract. A smaller vocal tract or resonating cavity will result in a higher pitch, for example. Women have a mean fundamental frequency of 180-250 Hertz (Hz) with an average fundamental frequency of 225 Hz.

### **Jitter (frequency perturbation)**

Frequency perturbation, or jitter, refers to the irregularities or variations in the cycles, often heard in dysphonic participants. The perceptual correlate of intensity is loudness, which is determined by the amplitude of the sound signal. The larger the amplitude, the more intense the sound signals and the greater perceived loudness (Roseberry-McKibbin et al., 2019).

### **Shimmer (amplitude perturbation)**

Amplitude perturbation, or shimmer refers to the variations in the cycle of vocal fold amplitude. This can be measured as a participant sustains a vowel. According to Roseberry-McKibbin et al., a speaker without vocal fold pathology should have a very small amount of shimmer (2019). Shimmer variation of more than 1 decibel is believed by some to make a patient sound dysphonic. A shimmer indicates total voice energy. Variation and is expressed in decibels. A “normal” value is less than 0. In contrast to  $F_0$ , shimmer is inversely proportional to intensity. Intensity of the voice depends on “closing of the vocal folds, the cordal tension, and the breathing puff” (Sinagra et al., 2004).

### **Maximum Phonation Time**

Maximum Phonation Time (MPT) refers to the ability to sustain “ah” for “as long as they can” (Roseberry-McKibbin et al., 2019). Average MPT for adults ages 18-39 is 20.90-24.60 seconds. MPT allows the clinician to observe adequacy of respiration, glottal

efficiency, and the possible presence of pathologies such as nodules (Roseberry-McKibbin et al., 2019). To obtain Maximum Phonation Time, full inspiration of /ah/ after a full inspiration at a constant pitch and intensity is therefore measured.

Similarly to work of Kim et al., (2012), the participant inhales and phonates from the lowest note to the highest note. The participant sustains the vowel /ah/ at a comfortable and constant pitch similarly to the work of Chun et al., 2012. Results are displayed using instrumentation on a monitor. The patient is comfortably seated on a chair and told to say /ah/ for 10 seconds with a comfortable level of effort that allowed the voice to be recorded with a microphone about 5 cm away. Fundamental frequency, jitter, and shimmer will be analyzed to see if values are within the normal range.

The Voice Handicap Index describes the participant's perception of her own voice. The Voice Handicap Index is a commonly utilized tool to rate an participant's voices and the effect her voice has on her life.

**Figure 1. Voice Handicap Index**

VOICE HANDICAP INDEX

Name: Samantha D'Agostino Date: 3/23/2018

These are statements that many people have used to describe their voices and the effects of their voices on their lives. Circle the response that indicates how frequently you have the same experience.

0-never      1-almost never      2-sometimes      3-almost always      4-always

**Part I-F**

My voice makes it difficult for people to hear me.	0	1	2	3	4
People have difficulty understanding me in a noisy room.	0	1	2	3	4
My family has difficulty hearing me when I call them throughout the house.	0	1	2	3	4
I use the phone less often than I would like to.	0	1	2	3	4
I tend to avoid groups of people because of my voice.	0	1	2	3	4
I speak with friends, neighbors, or relatives less often because of my voice.	0	1	2	3	4
People ask me to repeat myself when speaking face-to-face.	0	1	2	3	4
My voice difficulties restrict my personal and social life.	0	1	2	3	4
I feel left out of conversations because of my voice.	0	1	2	3	4
My voice problem causes me to lose income.	0	1	2	3	4
<b>SUBTOTAL</b>					<b>18</b>

**Part II-P**

I run out of air when I talk.	0	1	2	3	4
The sound of my voice varies throughout the day.	0	1	2	3	4
People ask, "What's wrong with your voice?"	0	1	2	3	4
My voice sounds creaky and dry.	0	1	2	3	4
I feel as though I have to strain to produce voice.	0	1	2	3	4
The clarity of my voice is unpredictable.	0	1	2	3	4
I try to change my voice to sound different.	0	1	2	3	4
I use a great deal of effort to speak.	0	1	2	3	4
My voice is worse in the evening.	0	1	2	3	4
My voice "gives out" on me in the middle of speaking.	0	1	2	3	4
<b>SUBTOTAL</b>					<b>17</b>

**Part III-E**

I am tense when talking to others because of my voice.	0	1	2	3	4
People seem irritated with my voice.	0	1	2	3	4
I find other people don't understand my voice problem.	0	1	2	3	4
My voice problem upsets me.	0	1	2	3	4
I am less outgoing because of my voice problem.	0	1	2	3	4
My voice makes me feel handicapped.	0	1	2	3	4
I feel annoyed when people ask me to repeat.	0	1	2	3	4
I feel embarrassed when people ask me to repeat.	0	1	2	3	4
My voice makes me feel incompetent.	0	1	2	3	4
I am ashamed of my voice problem.	0	1	2	3	4
<b>SUBTOTAL</b>					<b>22</b>

**TOTAL** 57

Score Range	Severity	Common Association
0-30	Mild	Minimal amount of handicap
31-60	Moderate	Often seen in patients with vocal nodules, polyps, or cysts
60-120	Severe	Often seen in patients with vocal fold paralysis or severe vocal fold scarring.

The Voice Handicap Index (VHI): Development and Validation. Barbara H. Jacobson, Alex Johnson, Cynthia Grywalski, Alice Silbergleit, Gary Jacobsen, Michael S. Benninger. American Journal of Speech-Language Pathology, Vol 6(3), 66-70, 1997. The Voice Handicap Index is reprinted with permission from all authors and ASHA. Copyright 1997-2001 American Speech-Language-Hearing Association.

## CHAPTER III

### RESULTS

#### **ENT Examination**

The participant visited an Ear Nose and Throat (ENT) doctor for assessment of laryngeal structures. Dr. Nelson Howard of University Hospitals examined the participant. Report as follows.

Flexible Laryngoscopy/Stroboscopy was performed to assess 1. diagnosis of symptomatic disorder involving the voice, swallow, upper aerodigestive tract, including OSA disorders, 2. preoperative evaluation of vocal cord function for participants undergoing surgery where the RLN or vagus nerves are at risk of injury, and/or 3. further evaluation of abnormalities of the upper aerodigestive tract discovered by another modality, such as CT, MRI, bronchoscopy or EGD.

#### **Physical Exam**

VOICE: moderate to severely decreased projection with breathy moderate hoarseness and moderate strain. Fundamental frequency 290 Hz, MPT 15 seconds

RESPIRATION: Breathing comfortably, no stridor.

EYES: EOM Intact, sclera normal.



NEURO: Alert and oriented times 3, Cranial nerves II-XII intact and symmetric bilaterally.

HEAD AND FACE: Symmetric facial features, no masses or lesions, sinuses nontender to palpation.

SALIVARY GLANDS: Parotid and submandibular glands normal bilaterally.

Anesthesia was used prior to laryngoscopy/stroboscopy composed of 4% lidocaine and 0.5% phenylephrine. After adequate afrin and lidocaine spray, the doctor advanced the endoscope via the nares. Assessment of the nasopharynx, base of tongue/vallecula, pyriform sinuses, post-cricoid area and pharyngeal walls were without lesion or mass.

Findings are as noted:

1. Arytenoid movement is largely symmetric bilaterally possibly slightly delayed on the right.
2. Closure is complete
3. Mucosal wave amplitude is asymmetric with increased right amplitude
4. Periodic
5. Pharyngeal wall contraction increased AP
6. No pooling of secretions
7. Mild post cricoid and AE fold edema
8. Well defined ventricles
9. Fundamental Frequency 290 Hz

Dr. Howard Summary

Twenty-four year old female with chronic hoarseness. Clinical exam today shows signs of reflux as well as muscle tension dysphonia. We discussed lifestyle changes for

laryngoesophageal reflux (LPR) and an instructions sheet was given We discussed using Gaviscon for reflux. We also discussed speech therapy to work on her projection. She has subtle changes viewed on stroboscopy suggesting a right vocal fold weakness. She does not recall significant voice issues post-thyroid surgery. She has an elevated pitch in speaking voice and poor endurance with speaking voice. She is usually quiet but noting increased demand with new profession as a SLP student.

**Cleveland State University (CSU) Examination**

The participant was examined to corroborate the findings of the ENT. The patient utilized a rigid laryngoscope for visualization of the laryngeal structures. Results via rigid scope videostroboscopy are displayed in Table I.

**Table I. Cleveland State University (CSU) Examination via Rigid Scope Videostroboscopy**


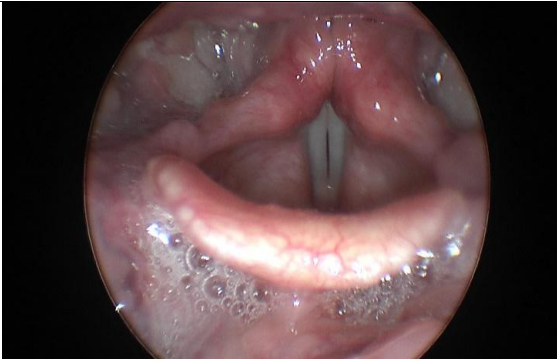
**Patient Info**

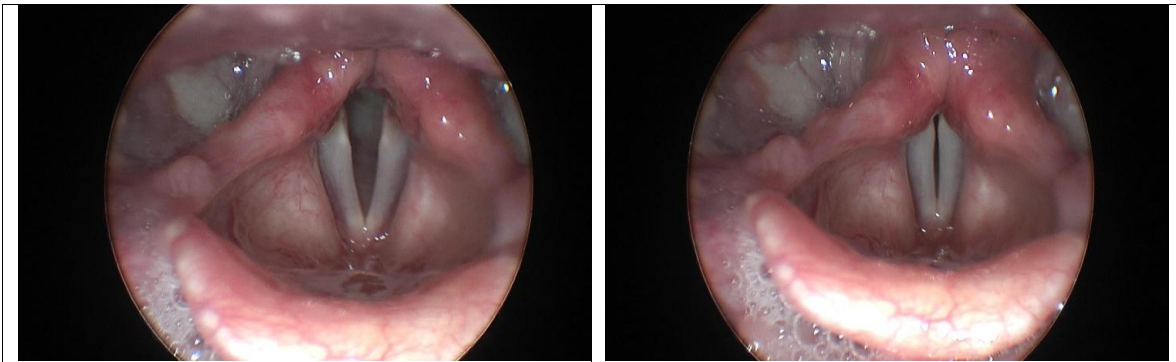
<b>Last Name:</b>	D'Agostino
<b>First Name</b>	Samantha

**Exam System Info - General**

<b>Exam Original Date:</b>	2/28/2019 5:08:10 PM	<b>Last Modified Date:</b>	3/21/2019 4:18:05 PM
<b>Examining Institution:</b>	Cleveland State University		

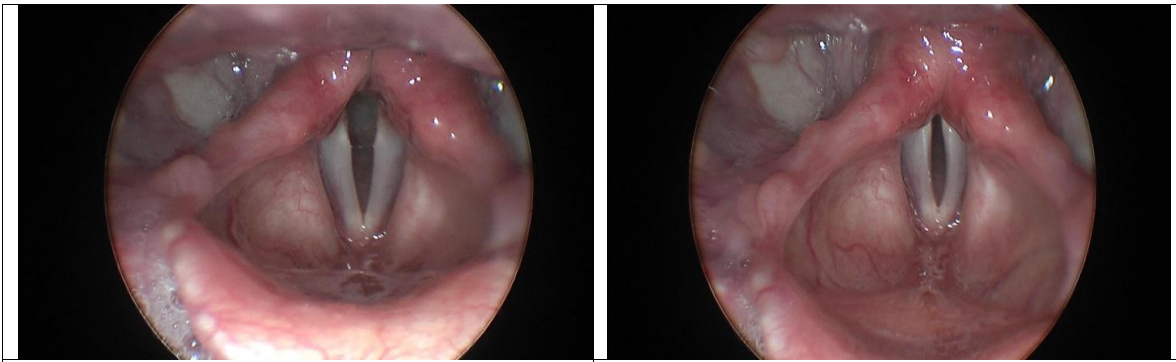
**Stills**

	
00:16:28 - Hourglass shape of vocal folds	00:18:14 – Spindle of vocal folds



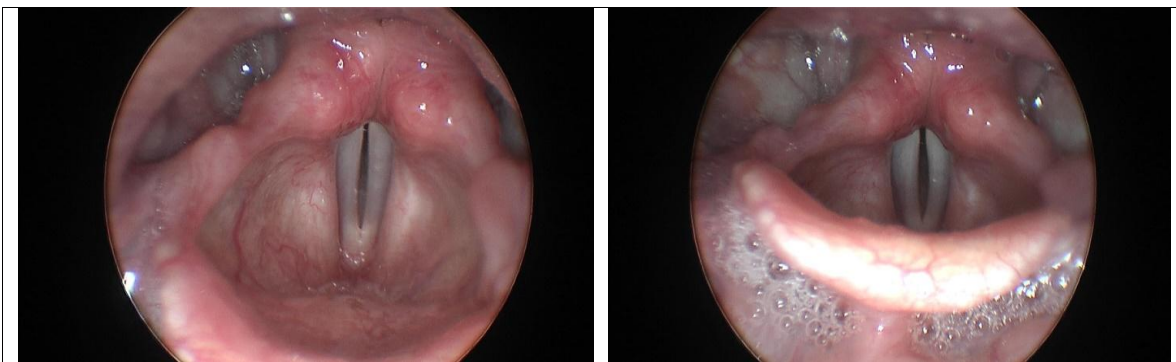
00:18:28 - LPR with posterior bumps:  
polyps? bilateral nodules? polypoid?

00:19:05 - Hourglass vocal folds.



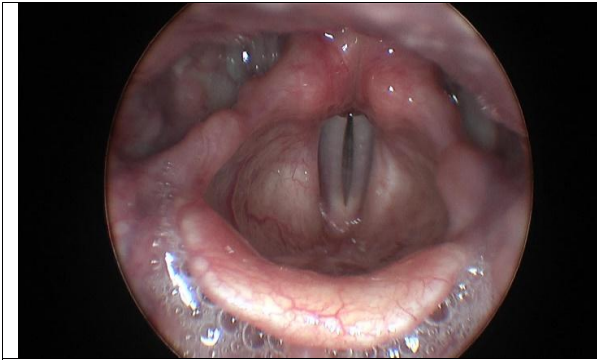
00:18:27 - Vascularity on the right  
false vocal fold. Swollen arytenoids  
with asymmetry.

00:19:12 – Spindle/bowing of vocal folds.

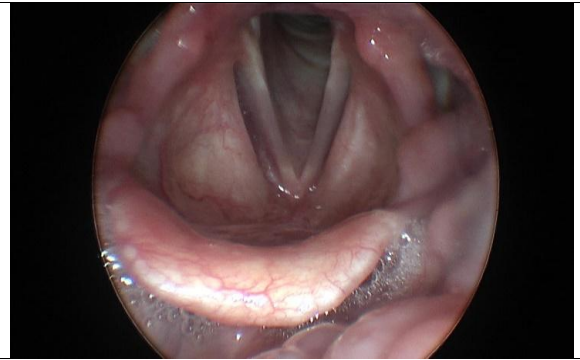


00:20:13 - Spindle of vocal folds.

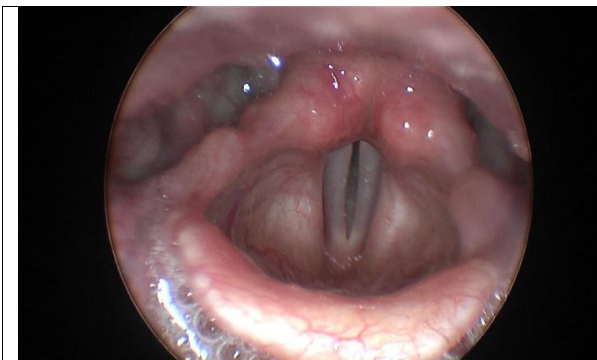
00:26:03 – Excess/copious secretions in  
valleculae, abnormal white appearance in  
the pyriforms.



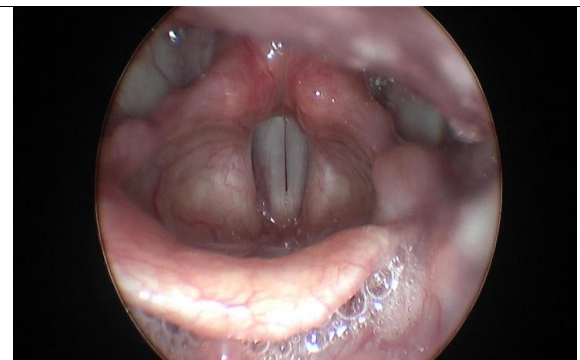
00:29:09 -Laryngeal vascularity and excessive secretions.



00:30:29 - Deep right ventricular fissure.



00:27:20 - Asymmetry in arytenoids, the right arytenoid more elongated. Left arytenoid appears to be swollen, with possible irritation from LPR.



00:40:24 - Thicker right vocal fold compared to left. Mucosal wave out of phase.

Comparison of ENT examination vs CSU imaging can be found in Table II.

**Table II. ENT vs CSU Results of Videostroboscopy:**

	ENT	CSU
<b>Arytenoids</b>	Asymmetry	Asymmetry
<b>Edema</b>	Edema noted	Edema noted
<b>Glottal Closure</b>	Complete	Incomplete
<b>Secretions</b>	No pooling noted	Excess secretions in valleculae/pyriforms
<b>Ventricle Appearance</b>	Increased vascularity	Increased vascularity
<b>Mucosal Wave</b>	Out of phase	Out of phase
<b>Fundamental Frequency</b>	290 Hz	268 Hz

Results from the ENT evaluation are similar to the CSU examination of the laryngeal area via videostroboscopic instrumentation for the exception of glottal closure and secretions present. The CSU examination reveal excess secretions in the valleculae/pyriforms. CSU examination reveals incomplete closure with a spindle gap. Glottal closure was categorized by the Voice-Vibratory Assessment with Laryngeal Imaging (VALI)-Stroboscopy (Poburka, Patel, & Bless, 2017). CSU examination results indicate typical posterior gap for a female, with irregular hourglass gap, spindle gap, and incomplete closure at times. Mucosal wave was agreed to be out of phase by both examinations. Increased vascularity, edema and asymmetric movement of arytenoids also warranted similar results concluded by both examinations.



**Figure 2. Voice-Vibratory Assessment with Laryngeal Imaging (VALI)-Stroboscopy**

Voice-Vibratory Assessment with Laryngeal Imaging (VALI) - Stroboscopy

Poburka, B., Patel, R., and Bless, D. 2016

Case #:		Confirm case #:	
<b>Glottal Closure</b>			
Definition:	Appearance of glottis during the most closed portion of the glottal cycle		
Rating:	Rate at normal pitch and loudness.		
<span>Complete</span> <span>Anterior Gap</span> <span>Posterior Gap</span> <span>Hourglass</span> <span>Spindle Gap</span> <span>Irregular</span> <span>Incomplete</span>			
<b>Amplitude</b>		<b>Mucosal Wave</b>	
Definition:	Magnitude of lateral movement of the vocal folds.	Definition:	Magnitude of movement of the muc. membrane.
Rating:	Rate at point of contact.	Rating:	Rate at normal pitch and loudness.
Right: _____ %	Left: _____ %	Right: _____	Left: _____
F0: _____ Hz.		F0: _____ (Hz.)	
<b>Non-vibrating Portion</b>		<b>Supraglottic Activity</b>	
Definition:	Adynamic segments of tissue that appears stiff.	Definition:	Constriction of supraglottic structures.
Rating:	Shade in affected area. Full ovals = 10% of TVF.	Rating:	Rate anteroposterior & mediolateral planes.
Right: _____ (ovals = 10%)	Left: _____	A-P: _____    ML: _____ F0: _____ (Hz.)	
<b>Vertical Level</b>			
Definition:	Do VFs meet on plane?		
Rating:	Circle one		
<span>on-plane</span> <span>off-plane; left lower</span> <span>off-plane; right lower</span>			
<b>Free Edge Contour</b>			
Definition:	Smoothness &/or straightness of free edge.		
Rating:	Rate right & left VFs separately during abduction. Write in one rating per vocal fold.		
<span>Normal</span> <span>Convex</span> <span>Concave</span> <span>Irregular</span> <span>Rough</span>			
Right: _____	Left: _____		

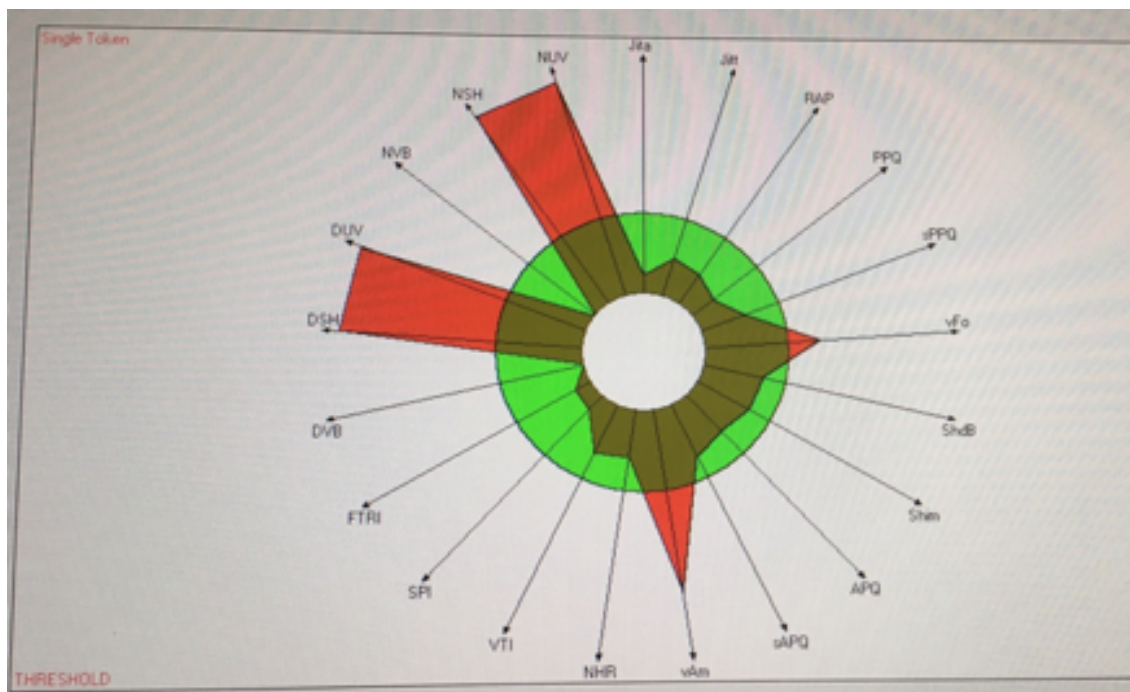
Visi-Pitch parameters are displayed in Table III. Acoustic analysis was applied following the participant sustaining /ah/ phoneme at a comfortable level. A voice report was generated along with a Multi-Dimensional Voice Diagram Visual Figure III.

**Table III. Visi-Pitch Measures**

<b>Parameter</b>	<b>Unit</b>	<b>Norm(f)/ STD(f)</b>	<b>Threshold</b>
Average Fundamental Frequency	Fo	268.150/27.457Hz	243.973
Mean Fundamental Frequency	MFo	268.085/25.107Hz	241.080
Average Pitch Period	ms	3.730/0.432ms	0.432
<b>Highest Fundamental Frequency</b>	Fhi	252.724/26.570Hz	340.171
Lowest Fundamental Frequency	Flo	234.861/28.968Hz	253.047
Standard Deviation from Fo	STD	4.008/2.722Hz	2.115
Phonatory Fo—Range in semitones	PFR	6/2.250	1.060
Fo Tremor Frequency	Fftr	2.878hz	1.964
<b>Parameter</b>	<b>Unit</b>	<b>Norm(f)/ STD(f)</b>	<b>Threshold</b>
Length of analyzed sample	Tsam	3.750s	3.000s
<b>Absolute Jitter</b>	Jita	26.927/16.654	83.200
<b>Jitter percent</b>	%	0.633/0.351	1.040
Relative Average Perturbation	RAP	0.387/0.214	0.680
Pitch Perturbation Quotient	PPQ	0.366	0.840
<b>Fundamental Frequency Variation</b>	<b>VFo</b>	1.495%/0.220	1.110
Shimmer in dB	ShdB	0.245/0.071	0.350
<b>Shimer Percent</b>	Shim	2.680/0.791	3.810

Amplitude Perturbation Quotient	APQ	1.397/0.527	3.070
<b>Peak to Peak Amplitude Variation</b>	<b>vAm</b>	<b>18.129%/10.743</b>	<b>8.200</b>
Noise to Harmonic Ratio	NHR	0.112/0.009	1.190
<b>Parameter</b>	<b>Unit</b>	<b>Norm(f)/ STD(f)</b>	<b>Threshold</b>
Voice Turbulence Index	VTI	0.046/0/0.12	0.061
<b>Soft Phonation Index</b>	SPI	7.543/4.133	14.120
<b>Fo-Tremor Intensity</b>	FTRI	0.183%/0/156	0.950
Degree of Voice Breaks	DVB	0.200/0.100	1.000
<b>Degree of Sub-harmonics</b>	DSH	0.200/0.100	1.000
<b>Degree of Voiceless</b>	DUV	3.336%/0.100	1.000
<b>Number of Voice Breaks</b>	NVB	0.200	0.900
<b>Number of Sub-harmonic Segments</b>	NSH	4.000/0.100	0.900
<b>Number of Unvoiced Segments</b>	NUV	4.000/0.100	0.900

**Figure 3. Multi-Dimensional Voice Diagram**





## CHAPTER IV

### DISCUSSION

Post-thyroidectomy, results reveal structural and perceptual voice changes via videostrobe instrumentation and voice analysis via Visi-Pitch. Although the participant does not have nerve damage reported, some atypical findings were noted via videostroboscopy imaging. Mucosal wave was consistently out of phase compared to normative movement. There is a “flutter” like movement of the right vocal fold, perhaps to compensate for reduced movement of the right arytenoid. This aligns with findings concluded by Stojadinovic et al., 2008a; Soylu et al., 2007; Henry et al., 2010) who discussed damage during thyroidectomy has an effect on voice and laryngeal structures and nerves such as the arytenoids without nerve damage. Singara et al., concluded that fatigue during phonation may be caused by increased effort to increase pitch (2004). This corroborates findings the participant noted, often attempting to achieve stronger vocal intensity, resulting in fatigue.

Slight anatomic changes are usually unnoticed during the operation but can produce phonatory changes perceived by the patients postoperatively (Sinagra et al., 2004). CSU results observe excess secretions/pooling within the valleculae and pyriform sinuses. Increased vascularity is observed on the right ventricular fold and the right true

vocal fold is thicker than the left. The pyriformis have an abnormal white appearance, perhaps due to scarring from laryngopharyngeal reflux. There is also edema of the laryngeal vestibule. A prominent/deep right ventricular fissure is noted, as are abnormal “bumps” on the posterior portion of the true vocal folds.

Jitter, shimmer, and fundamental frequency values were obtained via Visi-Pitch among other parameters. CSU average fundamental frequency is 268 Hz. This differs from the ENT report’s fundamental frequency of 290 Hz. Average F0 is 180-250 Hz. Both F0 are higher than the typical range. The participant is 4’11” and this height could contribute to elevated pitch in terms of a anatomically smaller larynx.

Voice breaks, number of unvoiced segments, fundamental frequency, and degree of voiceless and number of sub-harmonic breaks were observed to be outliers of typical voice parameters. **Table IV.** displays jitter, shimmer, fundamental frequency, and MPT parameters compared to the typical range.

**Table IV. Parameters vs Typical Range**

<b>Jitter</b>	<b>Shimmer</b>	<b>Fundamental Frequency</b>	<b>Maximum Phonation Time</b>
Participant 0.511%	Participant: 0.245 dB	Participant: ENT: 290 Hz CSU: 268 Hz	ENT: 15 seconds
Indicative of pathology: 1.040%	Typical Range: less than 1dB	Typical Range: 180-250 Hz	20.90-24.60 seconds

## CHAPTER V

### CONCLUSION

The participant noticed increased tension in the laryngeal area and difficulty projecting voice. She also noticed fatigue and voice breaks when attempting to project/sustain phonation for extended periods of time. Although the participant describes her vocal quality as soft at baseline, difficulty achieving loudness affects her daily life as a student in Speech-Language Pathology. Difficulty achieving loudness is likely due to hourglass/spindle gaps in glottal that impedes the build-up of subglottic pressure. Due to incomplete closure, air escapes and a weak/soft vocal quality results. Bowing of the vocal folds was also apparent in videostrobe imaging. Kim et al., (2012) suggested bowing of the EBSLN resulting in difficulty with high pitch phonation and incomplete glottic closure. Perhaps nerve damage occurred during surgery but was not reported, contributing to soft vocal quality and incomplete closure post-thyroidectomy. The participant's frequency experience vocal fatigue and her vocal quality is often described as "soft" by her and others. Similarly, research revealed that damage to EBSLN after surgery can cause fatigue, hoarseness, breathy voice, and/or nodules. Although nodules cannot be diagnosed, abnormal "bumps" were present on the free edge contour of the participant's vocal folds posteriorly.

Case studies are often limited in number of participants, as this study examined only one “case”. Future research should be conducted using instrumentation on a large sample of participants post-thyroidectomy to examine perceptual and acoustic parameters despite laryngeal nerve damage. Access to treatment options could be provided earlier if patients are aware of the possibility of structural and acoustic changes despite no reported laryngeal nerve damage. As previously mentioned, there are negative connotations associated with dysphonia. Voice disorders affect vocal pitch, loudness, and vocal quality. Although the participant noticed changes/difficulty with her voice post-operatively, she did not realize/pursue treatment options until her research on voice as a speech-language pathology student. Her difficulty achieving loudness, combined with vocal fatigue and soft vocal quality, prompted further investigation into her own voice. This study help identify perceptual and structural differences. It prompted investigation into treatment possibilities such as utilization of “twang” vocal quality to achieve loudness. Thyroid surgery and intubation is supported and well-researched to have an effect on the laryngeal structures and vocal quality. All in all, both perceptual and structural differences/abnormalities were observed in the participant following thyroidectomy despite preservation of the laryngeal nerve.

## REFERENCES

- Awan, S. N., Helou, L. B., Stojadinovic, A., & Solomon, N. P. (2011). Tracking voice change after thyroidectomy: application of spectral/cepstral analyses. *Clinical Linguistics & Phonetics*, 25(4), 302–320.  
<https://doi.org/10.3109/02699206.2010.535646>
- Chun, B.-J., Bae, J.-S., Chae, B.-J., Hwang, Y.-S., Shim, M.-R., & Sun, D.-I. (2012). Early Postoperative Vocal Function Evaluation After Thyroidectomy Using Thyroidectomy Related Voice Questionnaire. *World Journal of Surgery*, 36(10), 2503–2508. <https://doi.org/10.1007/s00268-012-1667-0>
- Henry, L. R., Helou, L. B., Solomon, N. P., Howard, R. S., Gurevich-Uvena, J., Coppit, G., & Stojadinovic, A. (2010). Functional voice outcomes after thyroidectomy: An assessment of the Dysphonia Severity Index (DSI) after thyroidectomy. *Surgery*, 147(6), 861–870. <https://doi.org/10.1016/j.surg.2009.11.017>
- Holler, T., & Anderson, J. (2014). Prevalence of voice & swallowing complaints in Pre-operative thyroidectomy patients: a prospective cohort study. *Journal of Otolaryngology - Head & Neck Surgery*, 43(1). <https://doi.org/10.1186/s40463-014-0028-4>
- Kashkouli, M. B., Pakdel, F., Kiavash, V., Heidari, I., Heirati, A., & Jam, S. (2011). Hyperthyroid vs hypothyroid eye disease: the same severity and activity. *Eye*, 25(11), 1442–1446. <https://doi.org/10.1038/eye.2011.186>
- Kim, S. W., Kim, S. T., Park, H. S., Lee, H. S., Hong, J. C., Kwon, S. B., & Lee, K. D. (2012). Voice Examination in Patients with Decreased High Pitch after

- Thyroidectomy. *Indian Journal of Otolaryngology and Head & Neck Surgery*, 64(2), 120–130. <https://doi.org/10.1007/s12070-012-0516-7>
- Koçak, Semih Aydın, S. (1999). Evaluation of Vocal Cord Function after Thyroid Surgery. *The European Journal of Surgery*, 165(3), 183–186. <https://doi.org/10.1080/110241599750007018>
- Lombard, L. E., & Steinhauer, K. M. (2007). A Novel Treatment for Hypophonic Voice: Twang Therapy. *Journal of Voice*, 21(3), 294–299. <https://doi.org/10.1016/j.jvoice.2005.12.006>
- Padur, A. A., Kumar, N., Guru, A., Badagabettu, S. N., Shanthakumar, S. R., Virupakshamurthy, M. B., & Patil, J. (2016). Safety and Effectiveness of Total Thyroidectomy and Its Comparison with Subtotal Thyroidectomy and Other Thyroid Surgeries: A Systematic Review. *Journal of Thyroid Research*, 2016. <https://doi.org/10.1155/2016/7594615>
- Park, J.-O., Bae, J.-S., Lee, S.-H., Shim, M.-R., Hwang, Y.-S., Joo, Y.-H., ... Sun, D.-I. (2016). The Long-Term Prognosis of Voice Pitch Change in Female Patients After Thyroid Surgery. *World Journal of Surgery*, 40(10), 2382–2390. <https://doi.org/10.1007/s00268-016-3511-4>
- Park, M. W., Baek, S.-K., Park, E.-H., & Jung, K.-Y. (2018). Long-term voice outcome after thyroidectomy using energy based devices. *Auris Nasus Larynx*, 45(3), 527–532. <https://doi.org/10.1016/j.anl.2017.08.007>
- Park, Y. M., Oh, K. H., Cho, J.-G., Baek, S.-K., Kwon, S.-Y., Jung, K.-Y., & Woo, J.-S. (2018). Changes in Voice- and Swallowing-Related Symptoms After

- Thyroidectomy: One-Year Follow-Up Study. *Annals of Otolaryngology & Rhinology & Laryngology*, 127(3), 171–177. <https://doi.org/10.1177/0003489417751472>
- Poburka, B. J., Patel, R. R., & Bless, D. M. (2017). Voice-Vibratory Assessment With Laryngeal Imaging (VALI) Form: Reliability of Rating Stroboscopy and High-speed Videoendoscopy. *Journal of Voice*, 31(4), 513.e1-513.e14. <https://doi.org/10.1016/j.jvoice.2016.12.003>
- Roseberry-McKibbin, C., Hegde, M. N., & Tellis, G. M. (2019). An Advanced Review of Speech-Language Pathology. Preparation for the Praxis SLP Comprehensive Examination. Fifth Edition. (Fifth Edition). PRO-ED.
- Simpson, C. B., May, L. S., Green, J. K., Eller, R. L., & Jackson, C. E. (2011). Vibratory Asymmetry in Mobile Vocal Folds: Is it Predictive of Vocal Fold Paresis? *Annals of Otolaryngology & Rhinology & Laryngology*, 120(4), 239–242. <https://doi.org/10.1177/000348941112000404>
- Sinagra, D. L., Montesinos, M. R., Tacchi, V. A., Moreno, J. C., Falco, J. E., Mezzadri, N. A., ... Curutchet, H. P. (2004). Voice changes after thyroidectomy without recurrent laryngeal nerve injury. *Journal of the American College of Surgeons*, 199(4), 556–560. <https://doi.org/10.1016/j.jamcollsurg.2004.06.020>
- Soylu, L., Ozbas, S., Uslu, H. Y., & Kocak, S. (2007). The evaluation of the causes of subjective voice disturbances after thyroid surgery. *The American Journal of Surgery*, 194(3), 317–322. <https://doi.org/10.1016/j.amjsurg.2006.10.009>
- Stojadinovic, A., Henry, L. R., Howard, R. S., Gurevich-Uvena, J., Makashay, M. J., Coppit, G. L., ... Solomon, N. P. (2008). Prospective trial of voice outcomes after thyroidectomy: Evaluation of patient-reported and clinician-determined voice

assessments in identifying post thyroidectomy dysphonia. *Surgery*, 143(6), 732–742. <https://doi.org/10.1016/j.surg.2007.12.004>

Sundberg, J., & Thalén, M. (2010). What is “Twang”? *Journal of Voice*, 24(6), 654–660. <https://doi.org/10.1016/j.jvoice.2009.03.003>

Sung, E. S., Kim, K. Y., Yun, B. R., Song, C. M., Ji, Y. B., Lee, J. C., & Tae, K. (2018). Long-term functional voice outcomes after thyroidectomy, and effect of endotracheal intubation on voice. *European Archives of Oto-Rhino-Laryngology*, 275(12), 3049–3058. <https://doi.org/10.1007/s00405-018-5145-7>

Vital, D., Morand, G. B., Meerwein, C., Laske, R. D., Steinert, H. C., Schmid, C., ... Huber, G. F. (2017). Early Timing of Thyroidectomy for Hyperthyroidism in Graves’ Disease Improves Biochemical Recovery. *World Journal of Surgery*, 41(10), 2545–2550. <https://doi.org/10.1007/s00268-017-4052-1>