



CSU  
College of Law Library

Cleveland State Law Review

---

Volume 7 | Issue 3

Article

---

1958

## The Mallet Finger Injury

Donald R. Pratt

Follow this and additional works at: <https://engagedscholarship.csuohio.edu/clevstrev>



Part of the [Health Law and Policy Commons](#), and the [Medical Jurisprudence Commons](#)

[How does access to this work benefit you? Let us know!](#)

---

### Recommended Citation

Donald R. Pratt, The Mallet Finger Injury, 7 Clev.-Marshall L. Rev. 448 (1958)

This Article is brought to you for free and open access by the Journals at EngagedScholarship@CSU. It has been accepted for inclusion in Cleveland State Law Review by an authorized editor of EngagedScholarship@CSU. For more information, please contact [library.es@csuohio.edu](mailto:library.es@csuohio.edu).

## The Mallet Finger Injury

Donald R. Pratt, M.D.\*

**SUMMARY:** Mallet finger is a permanent deformity caused by injury to the distal phalanx of a finger. Commonly seen in industrial accidents and in baseball players, the extending tendon is pulled off the bone of the terminal phalanx. Treatment consists of simple splinting (illustrated) in mild trauma, or surgical intervention when large bony fragments have been pulled off. If left untreated, some degree of drop finger ultimately develops. This disability varies in degree. Joint stiffness and deformity may result. A method of surgical treatment of more severe injuries is described.

The chief importance of this injury, to the lawyer, is in Workmen's Compensation cases. Understanding of its nature and long-range effects is needed in estimating the proper amount of compensation award.

**M**AN HAS LONG APPRECIATED the importance of his hands. As Dr. Sterling Bunnell so often said, activity of the hands is important in work and in play. Injuries to the hands present both functional disability and cosmetic problems.

Mallet finger deformity, or drop finger at the distal joint, is one of the most frequent injuries of the hand. Drop finger at the distal joint, the so-called "baseball finger," is the most common of all tendon ruptures—the insertion of the extensor tendon of the finger at the distal joint. During the past nine years our office has seen 252 cases of mallet finger deformity. They have all resulted from trauma. The trauma may be direct, from a laceration or contusion, or indirect, from sudden over-flexion of the distal joint of the finger while the extensor apparatus is actively contracted.

As to classification of mallet finger, according to cause, in this series of 252 consecutive cases, indirect trauma, or stubbing of the finger tip, accounted for 58% of the cases. Laceration of the extensor tendons caused 26% of the drop fingers, and crushing injuries to the tendon from direct trauma on the dorsum of the finger were found in 16% of the patients. In reviewing the case records it was noted that not only did the type of trauma vary, but the degree of trauma varied appreciably with each individual case. Thus the resultant extent of

---

\* Surgeon practicing in San Francisco; M.D. from Stanford University Medical School.

drop finger deformity varied considerably from patient to patient. In about 20% of the cases a bony fragment, varying in size, from the dorsal lip of the distal phalanx, was torn off with the pulled extensor tendon. Occasionally the bony fragment is wedged off by hyperextension of the terminal phalanx against the dorsum of the middle phalanx. It is interesting that in this series of cases of drop finger deformity the incidence was equally distributed between males and females. There was a wide age distribution, including a youngster two years of age, and an adult 78 years of age. By far the largest number of patients were in the adult group, between the ages of 36 and 49 years.

Since this condition has been commonly called a "baseball finger," careful investigation of this occupational hazard was undertaken. A survey of all of the players of one of the major league baseball teams was completed. A much higher than average incidence of mallet finger deformity was noted in baseball players. The numbers of the fingers involved were in direct relation to their period of playing and were highest in those baseball players who were catchers. Here mallet finger deformities, in varying degrees, were found in almost all of the fingers of the right hand. It is interesting to note in passing that a left-handed catcher is a rarity in organized baseball. Also it was noted that in those players who were more relaxed, direct trauma on the tips of their fingers many times did not result in a rupture, or even incomplete rupture, of the extensor apparatus. By relaxing the tension of the extensor tendon mechanism, injury from local trauma could be obviated. This is a significant training problem note, which might be considered by the general population as well.

The degree of trauma varies. The degree of rupture of the extensor apparatus varies. The incomplete rupture of the extensor apparatus is more frequently seen in ball players, so that the resultant drop finger deformity is less in the individual digits, and active treatment less indicated than in cases of more severe trauma or more complete tendon rupture. It is felt that the intact tendon fibres act to splint the joint internally, thus helping in nature's repair of the injured tendon fibres.

In this series of patients studied, the fingers were either seen early (on the day of injury, or within ten days after the

trauma) or late (after a period of inadequate, improper splinting, or without any treatment). Many of the patients looked on the injury, or immediate deformity, as probably transient or trivial in nature, and were reluctant to seek medical advice until many days had passed and the drop finger deformity had persisted.

The factors that determine the specific treatment for each individual case and that seem most likely to influence the ultimate function of the finger are: the type and degree of local trauma; the time interval between the injury and the proper medical attention; the presence and size of a bony fragment; and the actual age of the individual patient.

The problem is one of restoring continuity to the extensor mechanism at the distal joint of the finger. Full function can be restored if the retracted proximal end of the extensor tendon is accurately approximated to the terminal phalanx, or the distal stump of the tendon. This can be accomplished in many cases without surgery by bringing the tendon ends together, splinting the involved finger with slight hyperextension of the distal joint, and moderate flexion of the middle joint. Function of the extensor apparatus is preserved by early, effective splinting in this position for a period of five weeks. One physician with a moderate drop finger deformity simply taped his injured finger with the tip in the center of the palm, holding the finger in the recommended position for three weeks with an excellent result. Where the trauma is either mild, with rupture of only part of the tendon fibres in the extensor apparatus, or if the tendon fibres are divided by clean laceration, by placing the tendon ends in apposition in a relaxed position, prompt healing without reaction in the adjacent tissues will occur with adequate splinting.

It is obvious that if treatment is carried out late, one or two weeks after injury, or the aforementioned position of the finger is inadequately maintained, the injured tendon generally heals with paratenon in a lengthened manner, resulting in some degree of loss of function, or permanent mallet finger disability. This is often the case where the tendon is ruptured from a crushing type of injury, and a defect occurs in the tendon.

Primary surgical treatment of the lacerations, whether from clean cuts or from crushing trauma, is, of course, the treatment of choice. With this method of treatment in the crushing type of injuries, more accurate approximation of the divided tendon, or more reactionless healing of the surrounding traumatized tissue, can take place.

In cases of fracture, if the bony chip is tiny, it can generally be approximated simply, and satisfactorily, by bringing the tendon ends together by closed method of splinting. In a small percentage of mallet finger deformity, 36 cases in this series, or 14% of our cases, a large enough bony fragment of the dorsal lip of the distal phalanx was encountered requiring specific care. When the bony fragment is large, it involves considerable of the joint surface of the distal joint. Luxation of the terminal segment generally occurs with considerable distal joint surface deformity and ultimate permanent disability. Here the bony fragment should be reduced satisfactorily to restore alignment of the joint surfaces, and thus relieve the drop finger deformity. Since there is very little soft tissue across the dorsum of the distal joint over the terminal phalanges of the fingers, any sizeable bony deformity associated with tendon rupture or drop finger deformity, can readily be palpated. As the treatment of the mallet finger deformity is the same with or without a tiny bony chip, many of the fingers are not initially studied by x-ray. X-rays are generally taken only where there is obvious bony deformity, or there is a reasonable question of fracture. As the incidence of fractures of the dorsal lip of the distal phalanx are more frequent in the younger age group, x-rays are generally taken in these patients, or in the patients of the older age group where bony deformity is either obvious, or questionable. X-rays may show arthritic changes which ultimately contribute to the patient's permanent disability.

### **Types of Splinting**

Many methods of splinting have been described in the treatment of mallet finger. A simple flat tongue blade, or one modified with a pad on one end for hyperextension of the distal joint, is inadequate. Various metal splints with the distal segment of the finger hyperextended have been devised, and tried, unsatisfactorily. Numerous splints of padded wood, malleable steel, celluloid, collodion, plastic and "celastic," have been described and used. Since, in almost all cases, the distal joint must be moderately hyperextended, and the middle joint held in moderate flexion, to relax the extensor apparatus adequately, very few of these splints actually hold the finger in the desired position. Plaster of paris is widely used. Here, too, many objectionable features in the customary methods of applying plaster of paris casts are encountered. These casts are very difficult to apply,

they are generally clumsy, and there is danger of local areas of pressure, with circulatory embarrassment, swelling, and even pressure necrosis. These splints also frequently limit the activity of the adjacent digits, so that the rest of the hand sometimes stiffens. When plaster splints are applied carefully, and properly, in the form of a skeleton cast (after the method of Sterling Bunnell) using narrow wet strips across the volar aspect of the finger, and adding dorsal transverse bands, the plaster casts are generally satisfactory.

Because of the above-mentioned difficulties with the various methods of external splinting and casting, an internal splint method, using a longitudinal stainless steel Kirschner wire of medium calibre, .045 of an inch, was described by this author in January, 1951. (Fig. 1.) It has been used with success on a series of 92 cases of mallet finger. The wire is inserted with a small pistol-handle drill. In 1954 a cannulated guide was devised by Dr. Joseph T. Moreau of Edmonton, Canada, which has been used in the last 56 cases, obviating the difficulty in properly inserting the internal splint. The guide, here illus-




Fig. 1. Guide for insertion of Kirschner wire as an internal splint. (93 Am. J. Surg., 573-579, April 1957.)




Fig. 2. Positioning of the finger on guide and insertion of the wire splint. (93 Am. J. Surg., 573-579, April 1957.)

trated (Fig. 2), consists of a curved metal bar with three adjustable points of pressure, for holding the finger rigid, while the Kirschner wire is passed through the cannulated cylinder and drilled into the three phalanges of the finger. (Figs. 3 and 4.) The finger is thus manually lined up

by the guide in the desired position, the Kirschner wire is guided through the finger, in both the vertical and lateral planes, and the finger is securely splinted in the desired position. The course of the wire is predetermined by the alignment of the finger on the outrigger guide. The wire is inserted in the tip of the finger, drilled through all three phalanges of the finger, and is cut off with wire biters at the point it pene-

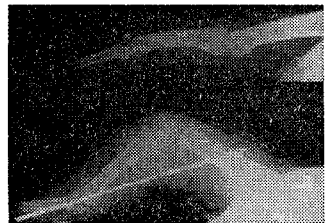


Fig. 3. (Upper), drop finger deformity with fracture of dorsal lip of phalanx. (Lower), reduction of fracture by withdrawable wire loop and immobilization by internal splint. (93 Am. J. Surg., 573-579, April 1957.)

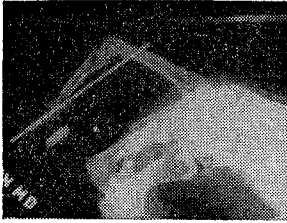


Fig. 4. Treatment of drop finger deformity by internal splint and reduction of fracture by withdrawable wire loop through the fracture site and distal joint. Note only slight hyperextension of distal joint and only 60 degrees of flexion of middle joint. (93 Am. J. Surg., 573-579, April 1957.)

trates the skin on the dorsum of the proximal segment of the finger. The wire can be withdrawn just enough so as not to be palpable on the dorsum of the proximal segment of the finger. The other end of the Kirschner wire on the tip of the finger then can be cut off squarely beneath the skin. The wire is completely buried and local irritation and infection are avoided. This internal splint comfortably immobilizes the injured finger in the proper position for the desired length of time, permits active

use of the adjacent digits, obviates any pressure on the finger, and can easily be removed from the tip of the finger in four or five weeks as an office procedure.

#### Methods of Treatment

Various methods of treatment were used even when the patient was seen on the day of injury. In general, where the extensor tendon was either ruptured or divided completely, simple application of the internal splint was found adequate. In those cases where the tendon rupture was incomplete, or where the patient was in the older age group and some stiffening of the joints might ultimately be expected, simple splinting with one of the new, form-fitting plastic molded splints was carried out for five weeks. (Figs. 5 and 6.) If the patients were first seen ten days or more after injury, the extensor tendons were generally approximated surgically with a single #34 stainless steel wire suture after the technique of Sterling Bunnell, fixed over a button or a notch in the tip of the finger nail and using a pull out wire, so that the suture could be withdrawn completely from the finger in four weeks.



Fig. 5. Two views of a simple plastic splint molded to fit the individual finger by moderate heat. A tiny ellipse is cut out in the proximal third to prevent a fold along the gutter of the splint.

In the late cases, the extensor mechanism was generally found healed by paratenon with increased length. Limitation of motion also resulted from adherence of the extensor apparatus across the dorsum of the middle phalanx, near the distal joint. In treating these late cases surgically, the paratenon bridging

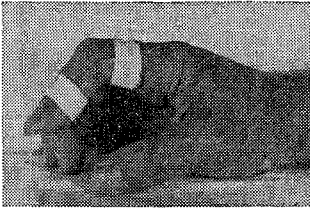


Fig. 6. The simple plastic splint applied by only two adhesive strips. Thus immobilizing the finger with the distal joint slightly hyperextended and the middle joint moderately flexed. Minimal immobilization.

the defect was resected so as to bring tendon fibres together, relieving the mallet finger deformity. In 16 cases a small flat sheet of non-irritating polythene (R) was placed beneath the tendon and the head of the middle phalanx, to prevent re-adherence. Six to ten weeks later the polythene (R) was generally removed, in the office under local anesthesia, leaving a smooth, synovial-like membrane beneath the tendon.

In those late cases where considerable paratenon was found, and too great a defect in the tendon structure would have resulted from resection of the paratenon, a "cinch" type of suture was placed back and forth across the tendon, in order to shorten it and so lessen the drop finger. This "cinch" suture is similar to those sutures placed in the eye muscles by the ophthalmological surgeon to shorten the tendons. This type of suture was used in 8 selected cases. A pull out suture of #34 stainless steel wire, placed withdrawable, was used, and resulted in useful extension of the distal joint, generally a range of 20° to 30° of motion. These cases, which occurred in the middle-aged group of patients, were treated many months after the initial injury.

Only a small percentage of the cases showed fractures of the dorsal lip of the distal phalanx, 36 cases or 14% of the entire series. Where the bony fragment was only a tiny fleck or chip, it was removed and the tendon approximated to the distal phalanx with the regular #34 withdrawable stainless steel wire tendon suture. When the bony fragment was of demonstrable size, specific care was necessary, placing a #34 wire loop about the fragment. One of the ends of the wire loop passed through the dorsal edge of the defect in the distal phalanx, and the other wire end through the distal joint space. This wire loop then drew the bony fragment into the defect of the distal phalanx. The ends of the wire loop were then fixed over a button on the center of the volar aspect of the distal segment of the finger. A withdrawable loop was placed out the dorsum. It was found that pulling the wire loop towards the tip of the finger did not satisfactorily reduce the fragment, so that the wire loop was fixed on the volar aspect of the finger, using a button to prevent tension on the skin of the volar aspect of the finger. This placed



the fragment in proper position. It was also found that in inserting the internal splint, special care must be taken to avoid popping the dorsal fracture fragment out, either by hyperextending the distal joint, or by pushing it out when the Kirschner wire splint was inserted. In treating the fractures in this manner, not only was the distal joint surface restored, but the volar luxation deformity of the distal phalanx was adequately reduced. This minimized the subjective symptoms, joint thickening and ultimate arthritis in this series of fracture cases.

### Conclusions

A series of mallet finger cases has been summarized. An internal splint providing satisfactory immobilization of the finger in the desired position with minimal difficulty for patient and operator has been described. If mallet finger deformity is left untreated, some degree of drop finger ultimately remains, permanent. In the untreated cases this disability varies in degree, with regard to the patient's activity and occupation. Subjective symptoms persist if there is joint stiffness, remaining bony deformity, or in the older age group of patients, where the degree of local trauma from a crush injury, or the persistent induration and cicatrization about the distal joint remains.

Drop finger deformity does not affect the strength or grip of the hand. Any weakness of grip present is related to residual stiffness and soreness in the finger joints associated with local cicatrix or underlying arthritis, rather than any mallet finger deformity per se. Not all injured fingers are studied radiographically.

Most types of external splints are either inadequate or fraught with complications. The internal splint, although it requires some dexterity in its insertion, has been found unusually satisfactory. When properly placed, there is no migration of the wire, since it is placed in all three phalanges of the finger, holding the two interphalangeal joints completely immobile. The internal splint permits activity of the adjacent fingers, and the hands are not encumbered by outside mechanical appliances, which often lead to stiffness of the adjacent fingers. It is a special adjunct in the postoperative management of the surgical case. No breaking of the wires has been encountered in the series of 92 cases. Only one pin was bent by sudden extreme forced flexion. In this case the pin was bent back straight before withdrawal.

Subjective symptoms persisting six months or more, consisting of general aching through the distal joint, local soreness across the dorsum of the middle phalanx, and residual stiffness of the fingers, followed treatment in 15 patients in the 42 to 68 year old age group. In six of the patients in the older age group, local swelling of the injured finger persisted for several months. In only one of the patients treated with the internal splint was the residual stiffness in the proximal interphalangeal joint persistent, the joint motion being limited to 75° of voluntary passive motion 18 months after the period of splinting. Subsequent to the treatment of this patient, care has been taken not to immobilize the middle joint in more than 60° of flexion, and not to hyperextend the distal joint beyond the limit of its circulation. This care has minimized the temporary stiffness in the middle joint, and obviated any circulatory embarrassment of the soft tissues across the dorsum of the distal joint.

Temporary local pin irritation about the skin on the dorsum of the proximal phalanx was encountered in five cases. These patients were in their early twenties and were quite active. The local irritation cleared up promptly by cutting the pin off 1, or 2 mms. shorter, beneath the skin. Any local skin irritation has been prevented in subsequent cases in this series. No irritation has been experienced at the tip of any of the fingers.

The use of polythene(®) and the "cinch-type" suture have been found adjuncts in the treatment of the late cases, providing a satisfactory range of motion in those cases which might ultimately have resulted in fair or poor end results.

It is agreed that we still have considerable to learn about tendon surgery, and specifically the management of the problem of mallet finger deformity. However, it is noted that by treating the cases early and by selecting the most advantageous method of treatment in each specific case, paying attention to the degree and type of trauma, the age of the patient, presence or absence of a fracture of the dorsal lip of the distal phalanx, the degree of contusion of the adjacent soft tissues, the presence of arthritides in the hand, and the willingness of the patient to do voluntary exercise after the period of immobilization, the degree of disability can be ultimately minimized.

It is interesting to note that those medical and legal problems confronting the hand surgeon, orthopedist, or industrial surgeon treating mallet finger deformities, are similar to those encountered by physicians and legal experts in cases of deformity and disability of other parts of the body.

### References

1. Bunnell, S., Primary repair of severed tendons; use of stainless steel wire. 47 *Am. J. Surg.*, 502-516 (1940).
2. Bunnell, S., *Surgery of the Hand*, 3rd ed. Philadelphia, 1956. J. B. Lippincott Co.
3. Bunnell, S., Intramedullary wire fixation of mallet finger. Discussion of paper by Casscells, S. W. and Strange, T. B. at Academy of Orthopedic Surgeons Meeting, Chicago, 1956.
4. Bunnell, S., Splints for the hand. In: *I Orthopaedic Appliances Atlas*, The American Academy of Orthopedic Surgeons, 317. Ann Arbor, Mich., 1952. J. W. Edwards Co.
5. Pratt, D. R., Internal splint for closed and open treatment of injuries of the extensor tendon at the distal joint of the finger. 34 *Am. J. Bone and Joint Surg.*, 785-788 (1952).
6. Pratt, D. R., Bunnell, S., and Howard, L. D., Mallet Finger—Classification and methods of treatment. 93 *Am. J. Surg.*, 573-579, (April 1957).
7. San Francisco Giants Baseball Team Club House, Seals Stadium, San Francisco, California. Personal communication with Manager William "Bill" Rigney, Trainer Frank "Doc" Bowman, and Players of the San Francisco Giants Baseball Team. June 1958.